

# Efficacy of a New Treatment Maneuver for Posterior Canal Benign Paroxysmal Positional Vertigo

Richard A. Roberts\*  
Richard E. Gans\*  
Renee L. Montaudo\*

## Abstract

Existing treatment maneuvers for posterior canal benign paroxysmal positional vertigo (PC-BPPV) include the Semont liberatory maneuver (SLM) and canalith repositioning maneuver (CRM). Independent investigations reveal that these maneuvers provide an excellent outcome for most patients. However, certain aspects of these maneuvers, such as hyperextension of the neck for CRM and brisk lateral motion for the SLM, are contraindicated for patients with vertebrobasilar insufficiency, cervical spondylosis, back problems, and so forth. A hybrid approach, the Gans repositioning maneuver (GRM) was developed for use with these patients. The purpose of this project was to assess efficacy of the GRM for treatment of PC-BPPV. Two-hundred seven participants were enrolled in this prospective study. All participants were treated with the GRM. Six different clinicians performed the treatments. Participants returned for follow-up at one-week intervals until it was determined that the PC-BPPV was clear. On average, 1.25 GRM treatments were required to resolve the PC-BPPV. The majority of the participants (80.2%) were cleared with one GRM treatment, and 95.6% were clear after two treatments. Recurrence rate was 5%. There was no difference in outcome based on clinician. The GRM is an efficacious treatment maneuver for PC-BPPV and may be preferential for use in patients with neck, back, hip, and/or mobility issues that contraindicate the use of SLM or CRM.

**Key Words:** Benign paroxysmal positional vertigo, canalith repositioning maneuver, otoconia, semicircular canal

**Abbreviations:** BPPV = benign paroxysmal positional vertigo; CRM = canalith repositioning maneuver; GRM = Gans repositioning maneuver; PC-BPPV = posterior canal benign paroxysmal positional vertigo; SLM = Semont liberatory maneuver

## Sumario

Maniobras existentes para el tratamiento del vértigo posicional paroxístico benigno del canal posterior (PC-BPPV) incluyen la maniobra liberadora de Semont (SLM) y la maniobra de reposicionamiento de los otolitos del canal (CRM). Investigadores independientes revelan que estas maniobras aportan resultados excelentes para la mayoría de los pacientes. Sin embargo, ciertos aspectos de estas maniobras, tales como la hiper-extensión del cuello en la CRM y el movimiento lateral brusco para la SLM, están contraindicadas en

---

\*American Institute of Balance, Seminole, FL

Richard A. Roberts, Ph.D., American Institute of Balance, 11290 Park Boulevard, Seminole, FL 33772; Phone: 727-398-5728; Fax: 727-398-4914; E-mail: rroberts@dizzy.com

Portions of this work were presented at the 28th annual midwinter research meeting of the Association for Research in Otolaryngology, New Orleans, LA, February 19–24, 2005; the American Academy of Audiology's 17th Annual Convention and Exposition, Washington, D.C., March 30–April 2, 2005; and the 57th annual meeting of the American Academy of Neurology, Miami Beach, FL, April 9–16, 2005.

pacientes con insuficiencia vertebro-basilar, con espondilosis cervical, con problemas de espalda, y demás. Un enfoque híbrido, la maniobra de reposicionamiento de Gans (GRM) se desarrolló para utilizarla con estos pacientes. El propósito de este proyecto fue evaluar la efectividad de la GRM para el tratamiento de la PC-BPPV. Doscientos siete pacientes fueron involucrados en este estudio prospectivo. Todos los pacientes fueron tratados con la GRM. Seis médicos diferentes realizaron el procedimiento. Los participantes regresaron para control a intervalos de una semana hasta que se determinó que su PC-BPPV estaba resuelta. En promedio, se requirieron 1.25 tratamientos con GRM para resolver la PC-BPPV. La mayoría de los participantes (80.2%) fueron dados de alta con un tratamiento de GRM y 95.6% después de dos tratamientos. La tasa de recurrencia fue de 5%. No existieron diferencias en los resultados en relación con los médicos. La GRM es una maniobra de tratamiento eficaz para el PC-BPPV y puede estar indicada de preferencia para pacientes con problemas de cuello, espalda, cadera o con problemas de movilidad en general, que contraindican el uso de la SLM o la CRM.

**Palabras Clave:** Vértigo posicional paroxístico benigno, maniobra de reposicionamiento de otolitos del canal, otoconia, canal semicircular

**Abreviaturas:** BPPV = vértigo posicional paroxístico benigno; CRM = maniobra de reposicionamiento de otolitos del canal; GRM = maniobra de reposicionamiento de Gans; PC-BPPV = vértigo posicional paroxístico benigno del canal posterior; SLM = maniobra liberadora de Semont

**B**enign paroxysmal positional vertigo (BPPV) is the most common cause of vertigo (Bath et al, 2000). It is now widely accepted that individuals exhibit symptoms of BPPV when calcium carbonate crystals, known as otoconia, become displaced from the utricle of the inner ear and move into the semicircular canal(s) (Hall et al, 1979; Parnes and McClure, 1992). The presence of the debris causes the involved semicircular canal to become sensitive to changes in orientation of the head in the plane of the canal. The classic symptoms of BPPV include brief episodes of intense positionally provoked vertigo. The vertigo is typically accompanied by upbeating, rotary-torsional nystagmus with the superior pole of the eyes beating towards the affected ear during the fast phase. This type of nystagmus occurs given the connection of the posterior semicircular canal to the superior oblique and inferior rectus extraocular muscles. The posterior semicircular canal is the most often involved canal due to its anatomical location inferior to the utricle (Korres et al, 2002). Posterior canal BPPV (PC-BPPV) accounted for 90% of 122 consecutive cases of BPPV in Korres et al.

It is well established that effective treatment maneuvers exist for PC-BPPV (Semont et al,

1988; Epley, 1992). Though the methods proposed by Semont et al (1988) and Epley (1992) differ to an extent in their positions, the goal of both maneuvers is to move the displaced otoconial debris around the long arm of the posterior canal, through the common crus, and back into the utricle. Regardless of study, most investigators report that these repositioning maneuvers are highly efficacious at clearing the debris from the canal and, thus, alleviating the symptoms experienced by the patient (Macias et al, 2000; Nunez et al, 2000; Ruckenstein, 2001; Gans and Harrington-Gans, 2002; Pollak et al, 2002; Korres and Balatsouras, 2004; Steenerson et al, 2005). These methods are easily tolerated by many individuals with PC-BPPV.

Although BPPV is common in patients over 50, it is even more prevalent in the older population (Korres et al, 2002). This population may have comorbid factors that should be considered prior to assessment and, ultimately, treatment of BPPV. Vertebrobasilar insufficiency, cervical spondylosis, limited range of motion, and so on, are all factors that are commonly encountered in the older population. Humphriss et al (2003) suggested that the commonly utilized Dix-Hallpike maneuver is contraindicated in patients with such

comorbid factors. The Dix-Hallpike maneuver requires positioning of the patient so that the head is off the exam table (Dix and Hallpike, 1952). This positioning places the neck of the patient in hyperextension. Humphriss et al (2003) suggested a side-lying maneuver in which the head and neck of the patient are fully supported on the exam table as an alternative for assessment of BPPV. Cohen (2004) agrees with the report by Humphriss et al that the side-lying maneuver is an appropriate alternative for such patients with these comorbid factors.

These reports have bearing on the current study in that the first position of the Epley (1992) maneuver and its modifications, collectively referred to herein as “canalith repositioning maneuvers” (CRMs), is the Dix-Hallpike maneuver. Clearly, if the Dix-Hallpike maneuver is contraindicated for assessment of BPPV in these patients, then CRM treatments are also contraindicated because the neck of the patient is maintained in a hyperextended position for an even longer period of time than is typically required for assessment with the Dix-Hallpike. Although Epley (1992) indicated that his patients were in each position for only 6–13 sec, the fact is most investigators report leaving patients in CRM positions for longer durations ranging from 2 min (Ruckenstein, 2001) to 4 min (Herdman et al, 1993; Tirelli et al, 2000).

An excellent alternative to the CRM treatments for these patients is the Semont liberatory maneuver (SLM) (Semont et al, 1988). The first position of the SLM incorporates a side-lying maneuver as advocated by Humphriss et al (2003) and Cohen (2004). However, the second position of the SLM incorporates a brisk lateral motion in which the body of the patient is moved en masse from the involved side to the uninvolved side. This brisk motion is contraindicated for patients with hip, back, or other issues that may affect mobility (i.e., obese patients). Interestingly, the CRM also has the patient move onto the uninvolved side, but with a simple roll from supine to the uninvolved side. This positioning is seemingly much easier for such patients to accomplish. Obviously, patients in the older population may exhibit factors that at least make it difficult and at most contraindicate use of either the CRM or the SLM. It is this reality that no doubt led Sakata et al (2004) to state that the Epley or Semont maneuvers should never be performed

on elderly patients. This is an unfortunate statement, as the older population is not only more likely to present with BPPV but may also be more likely to experience a fall due to abnormal postural stability contributed to by BPPV (Oghalai et al, 2000).

The finding that some patients exhibit factors that contraindicate use of the CRM (vertebrobasilar insufficiency, cervical spondylosis, etc.) or the SLM (back problems, mobility issues, etc.), led to the development of a hybrid treatment approach for PC-BPPV called the Gans repositioning maneuver (GRM). The GRM incorporates the side-lying maneuver as its first position. This is similar to the SLM and avoids hyperextension of the neck found with the CRM. As shown in Figure 1, the head of the patient is turned 45° away from the affected ear, and the patient is moved into a side-lying position on the involved side. The second position is a roll from the involved side to the uninvolved side. This is similar to the positioning used in the CRM. A liberatory headshake is then performed as suggested by Semont et al (1988). Finally, the patient is returned to an upright, seated position.

The purpose of the current investigation was to determine if the GRM is an efficacious treatment maneuver for PC-BPPV. Specifically, we wanted to ensure that this hybrid approach was able to clear otoconial debris from patients with a level of outcome similar to that reported for SLM and CRM (Semont et al, 1988; Epley, 1992; Herdman et al, 1993). The recurrence rate is another factor that required consideration, as well as whether different clinicians have similar patient outcome.

## METHODS

### Participants

All 207 adult participants were recruited from patients seen at the American Institute of Balance between 2001 and 2004. Participants were provided with and signed an informed consent document prior to enrollment in the study. Age ranged from 27–94 years with an average age of 71 years. 130 participants were female, and 77 were male. Posterior canal BPPV was confirmed in all participants with video-oculography recording. 121 participants had right ear involvement, 76 had left ear involvement, and 10 had bilateral PC-BPPV.

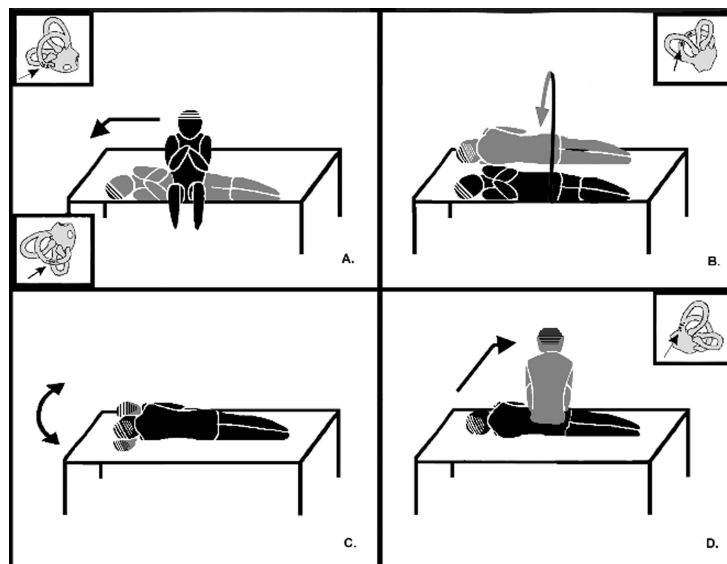
## Procedures

Participants were treated with the GRM as shown in Figure 1. Treatments were conducted by six different clinicians (including the three authors) experienced in treatment of PC-BPPV using SLM and CRM. All clinicians were instructed in use of the GRM. Participants received one GRM treatment per appointment and returned for follow-up evaluation at one-week intervals. Participants with bilateral involvement had ears treated on separate occasions. All participants received postmaneuver activity restrictions, which was part of our protocol at the time. These restrictions included avoidance of the following: vertical head movements for 24 hours, sleeping supine with the head elevated to a 30° angle for first night post-treatment, and sleeping on treated side for the first three nights post-treatment. We have since eliminated postmaneuver restrictions (Roberts et al, 2005). Participants were judged to be “clear” of the PC-BPPV when there was no nystagmus or subjective vertigo elicited by diagnostic positioning at the follow-up appointment.

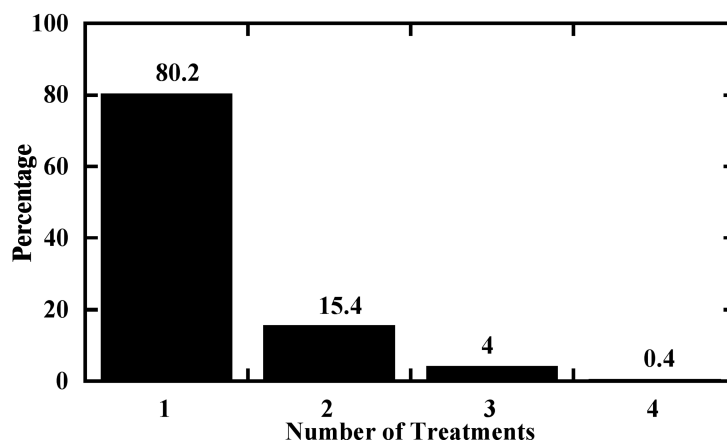
## RESULTS

As shown in Figure 2, 80.2% of the 207 participants were clear of PC-BPPV after one GRM treatment, with another 15.4% clear after a second treatment. The remaining 4.4% required a third or fourth treatment. The average age of participants cleared in one treatment was 71 years. The average age of participants cleared in two treatments was 75 years, while this average was 68 years for participants requiring three to four treatments. These results suggest no apparent effect of age in determining outcome efficacy. All participants were cleared within four treatments. On average, 1.25 treatments were required to clear the 207 participants.

Only 5% of the participants experienced recurrence of PC-BPPV following initial clearance by GRM. Participants included in the study have been followed for a period from ten months to three years, seven months. Recurrences occurred within a range three months to 24 months following clearance of BPPV (mean ten months, 27 days; standard deviation six months, 18 days).



**Figure 1.** Gans repositioning maneuver positioning sequence is shown for hypothetical right posterior canal benign paroxysmal positional vertigo. (A) Patient is in primary position seated and facing forward. Position 1: Head turned 45° to left and placed in a side-lying position on right side. Otolith debris moves to center of posterior canal. (B) Position 2: Patient rolled from right side to left side with head maintained in position 45° to left. Otolith debris moves to common crus. (C) Liberatory headshake: After provocation of symptoms elicited by Position 2, patient instructed to shake head side-to-side three or four times. Otolith debris traverses common crus. (D) Position 3: Patient is returned to primary position. Body brought to seated position with head turned forward to center position. Otolith debris enters utricle.



**Figure 2.** Percentage of patients cleared of posterior canal benign paroxysmal positional vertigo over the number of treatments.

Six different clinicians treated the 207 participants. Outcome per clinician is shown in Figure 3. A one-way analysis-of-variance (ANOVA) revealed no effect of clinician [ $F(5, 201) = 1.44; p = 0.21$ ].

## DISCUSSION

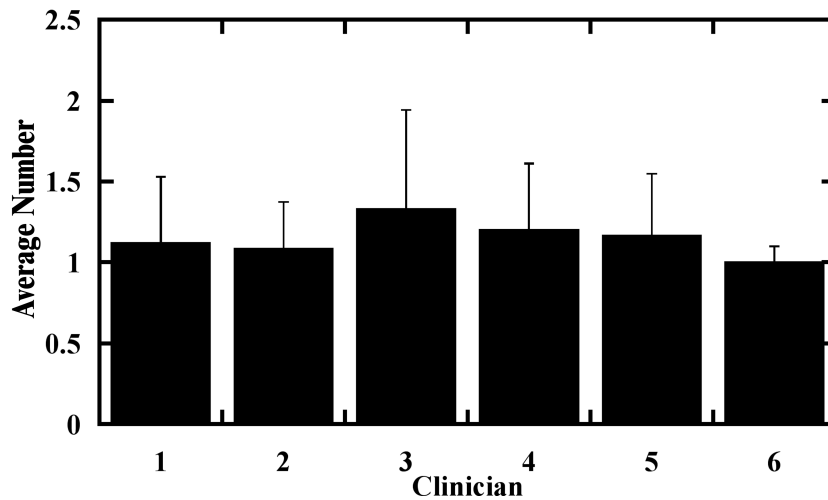
Results from the current study indicate that the GRM is successful in clearing PC-BPPV. Approximately 96% of patients were clear within one or two treatments. This compares well with data reported in previous studies of treatment maneuvers for PC-BPPV (see Table 1). For a series of 711 patients, Semont et al (1988) reported that 84% were clear of PC-BPPV following a single SLM. Ninety-three percent were clear after two treatments. Herdman et al (1993) and Gans and Harrington-Gans (2002) report slightly lower rates of success using a single SLM for PC-BPPV. These rates are obviously lower than that reported for the GRM in the current study. Herdman et al (1993) reports

70% success in 30 patients, and Gans and Harrington-Gans (2002) report 63% success in 220 patients. With a second treatment, Gans and Harrington-Gans (2002) improved the success rate to 73%. Herdman et al (1993) did not perform a second treatment, as they were interested in outcome with only a single treatment. It is noted that in both studies, an even larger percentage of patients noticed improvement in symptoms with the SLM but were not reported as cleared of the BPPV.

Some investigations describing outcome with CRM methods are comparable to results from the current study using GRM. Epley (1992) states that 90% of 30 patients were cleared of PC-BPPV and all vertigo/nystagmus following treatment with CRM. Of course, per his protocol, the patients actually received multiple treatments during a single appointment. Participants in the current study received a single GRM treatment during each appointment. Herdman et al (1993) reports only 57% success in 30 patients with a single CRM treatment. Gans and

**Table 1. Comparison of Data from Previous Studies Using Semont Liberatory Maneuver (SLM) and Canalith Repositioning Maneuver (CRM) to the Results Obtained Using the Gans Repositioning Maneuver (GRM) on Treatment of Posterior Canal Benign Paroxysmal Positional Vertigo**

Study	Treatment	n	Percentage of Patients Clear		Percentage Recurrence
			One Treatment	Two Treatments	
Semont et al (1988)	SLM	711	84	93	4
Epley (1992)	CRM	30	90	–	30
Herdman et al (1993)	SLM	30	70	–	10
	CRM	30	57	–	10
Gans and Harrington-Gans (2002)	SLM	220	63	73	5
	CRM	161	76	92	14
Current Study	GRM	207	81	96	5



**Figure 3.** Average number of treatments each clinician needed to clear posterior canal benign paroxysmal positional vertigo. Error bars represent standard deviation.

Harrington-Gans (2002) report 76% success in 161 patients with a single CRM treatment, and their outcome was 92% for the same group of patients following a second CRM. This data is more in line with Epley (1992) and results from the current study for GRM.

Participants treated in the current investigation have been monitored for recurrence of PC-BPPV over a period of time up to approximately 3.5 years. During this time, 5% of the participants have experienced a recurrence of PC-BPPV. This is similar to the recurrence rate of 4.22% reported by Semont et al (1988) for the SLM. Gans and Harrington-Gans (2002) reported a 5% recurrence rate for their patients treated with SLM. Herdman et al (1993) indicated a recurrence rate of 10% for patients treated with SLM. Rates of recurrence appear to be somewhat higher for patients treated with CRM compared to most reports for SLM or GRM. Rates for CRM range from 10–30% (Epley, 1992; Herdman et al, 1993; Gans and Harrington-Gans, 2002).

It is interesting that the GRM has a recurrence rate similar to that of the SLM. Overall, it appears that these rates are approximately 5%, although Herdman et al (1993) reported a 10% rate of recurrence for their participants treated with SLM. In addition to side-lying as the first position during both treatments, a liberatory headshake motion is also utilized in both. Semont et al (1988) stated that if no response was provoked following the brisk lateral motion to the uninvolved side, the head of the patient is slowly turned 90° facing

upward and then quickly turned 45° facing downward. In the GRM, the patient is rolled onto the uninvolved side and then instructed to shake the head back and forth three to four times. In our own clinic, we have observed patients whose symptoms did not provoke when rolled onto the uninvolved side but had a strong response following the liberatory headshake. Tirelli et al (2000) incorporated head shaking on each position of their treatment procedure and realized a significant improvement in treatment outcome compared to controls who did not undergo headshake. Both Tirelli et al (2000) and Herdman et al (1993) suggest that the headshake may dislodge or otherwise free any adherent otoconial debris. It is certainly possible that inclusion of the liberatory headshake offers some enhancement to the treatment outcome. This aspect of the GRM and SLM is worthy of future study.

Only 10 of the 207 participants included in this study had bilateral PC-BPPV. The average number of treatments needed to clear both ears of these participants was 1.1, which is comparable to the 1.25 treatments needed, on average, to treat the entire group of participants. Only two of the bilateral participants experienced a recurrence. One experienced a recurrence of left PC-BPPV four months after clearance was demonstrated, and the second had a recurrence of left PC-BPPV six months after clearance. Neither patient experienced a recurrence of right PC-BPPV.

In the current investigation, six different clinicians performed the treatments. There

was no difference in outcome depending on which clinician performed the GRM. Multiple independent studies exist in the literature, and these indicate that both the SLM and the CRM offer excellent outcome (Macias et al, 2000; Ruckenstein, 2001; Korres et al, 2002; Salvinelli et al, 2004). This certainly suggests that, like the GRM in the current study, there is no effect of clinician for the SLM or the CRM.

## SUMMARY AND CONCLUSIONS

The GRM is a new treatment maneuver for PC-BPPV. It is a hybrid of the SLM and the CRM and may be preferential for use in patients with neck, back, hip, mobility issues, and so on that contraindicate the use of these established maneuvers. Results from the current investigation indicate the following: (1) on average, 1.25 treatments were needed to clear PC-BPPV from 207 participants, (2) 80–96% of the participants were clear with one or two GRM treatments, (3) a recurrence rate of 5% is observed over a period of greater than 3.5 years, and (4) no clinician effect was observed.

**Acknowledgments.** The authors wish to thank Drs. Patricia Harrington-Gans, Allison H. Kastner, and Susan Good-Smith for assistance in treating the participants in the current study. Our appreciation is also expressed to Dr. Allison Kastner and Ed Grady for assistance with the schematic of the Gans repositioning maneuver.

## REFERENCES

Bath A, Walsh R, Ranalli P, Tyndel F, Bance M, Mai R, Rutka J. (2000) Experience from a multidisciplinary “dizzy” clinic. *Am J Otol* 21:92–97.

Cohen H. (2004) Side-lying as an alternative to the Dix-Hallpike test of the posterior canal. *Otol Neurotol* 25:130–134.

Dix R, Hallpike C. (1952) The pathology, symptomatology and diagnosis of certain common disorders of the vestibular system. *Ann Otol Rhinol Laryngol* 6:987–1016.

Epley J. (1992) The canalith repositioning procedure: for treatment of benign paroxysmal positional vertigo. *Otolaryngol Head Neck Surg* 119:399–404.

Gans R, Harrington-Gans P. (2002) Treatment efficacy of benign paroxysmal positional vertigo (BPPV) with canalith repositioning maneuver and Semont Liberatory Maneuver in 376 patients. *Semin Hear* 23:129–142.

Hall S, Ruby R, McClure J. (1979) The mechanics of benign paroxysmal vertigo. *J Otolaryngol* 8:151–158.

Herdman S, Tusa R, Zee D, Proctor L, Mattox D. (1993) Single treatment approaches to benign parox-

ysmal positional vertigo. *Arch Otolaryngol Head Neck Surg* 119:450–454.

Humphriss R, Baguley D, Sparkes V, Peerman S, Moffat D. (2003) Contraindications to the Dix-Hallpike manoeuvre: a multidisciplinary review. *Int J Audiol* 42:166–173.

Korres S, Balatsouras D. (2004) Diagnostic, pathophysiological, and therapeutic aspects of benign paroxysmal positional vertigo. *Otolaryngol Head Neck Surg* 131:438–444.

Korres S, Balatsouras D, Kaberos A, Economou C, Kandiloros D, Ferekidis E. (2002) Occurrence of semicircular canal involvement in benign paroxysmal positional vertigo. *Otol Neurotol* 23:926–932.

Macias J, Lambert K, Massingale S, Ellensohn A, Fritz J. (2000) Variables affecting treatment in benign paroxysmal positional vertigo. *Laryngoscope* 110:1921–1924.

Nunez R, Cass S, Furman J. (2000) Short- and long-term outcomes of canalith repositioning for benign paroxysmal positional vertigo. *Otolaryngol Head Neck Surg* 122:647–652.

Oghalai J, Manolidis S, Barth J, Stewart M, Jenkins H. (2000) Unrecognized benign paroxysmal positional vertigo in elderly patients. *Otolaryngol Head Neck Surg* 122:630–634.

Parnes L, McClure J. (1992) Free-floating endolymph particles: a new operative finding during posterior semicircular canal occlusion. *Laryngoscope* 102:988–992.

Pollak L, Davies R, Luxon L. (2002) Effectiveness of the particle repositioning maneuver in benign paroxysmal positional vertigo with and without additional vestibular pathology. *Otol Neurotol* 22:79–83.

Roberts R, Gans R, DeBoodt J, Lister J. (2005) Treatment of benign paroxysmal positional vertigo: necessity of postmaneuver patient restrictions. *J Am Acad Audiol* 16:357–366.

Ruckenstein M. (2001) Therapeutic efficacy of the Epley canalith repositioning maneuver. *Laryngoscope* 111:940–945.

Sakata E, Ohtsu K, Sakata H. (2004) Pitfalls in which otolaryngologists often are caught in the diagnosis and treatment of vertigo. *Int Tinnitus J* 10:31–34.

Salvinelli F, Trivelli M, Casale M, Firrisi L, Di Peco V, D’Ascanio L, Greco F, Miele A, Petitti T, Bernabei R. (2004) Treatment of benign positional vertigo in the elderly: a randomized trial. *Laryngoscope* 114:827–831.

Semont A, Freyss G, Vitte E. (1988) Curing the BPPV with a liberatory maneuver. *Adv Otorhinolaryngol* 42:290–293.

Steenerson R, Cronin G, Marbach P. (2005) Effectiveness of treatment techniques in 923 cases of benign paroxysmal positional vertigo. *Laryngoscope* 115:226–231.

Tirelli G, D’Orlando E, Zarccone O, Giacomarra V, Russolo M. (2000) Modified particle repositioning procedure. *Laryngoscope* 100:462–468.